

# Let the Light In

## Simple steps for achieving lifelike restorations

by Daniel J. Poticny, DDS



**Daniel J. Poticny, DDS**, is an adjunct clinical associate professor at the University of Michigan School of Dentistry, department of cariology, restorative sciences, and endodontics, with a full-time practice in Dallas.

He is an international presenter and educator for digital dentistry and materials, adhesives and cements, and restorative dentistry. He is widely published on these topics in addition to performing original and ongoing dental research.

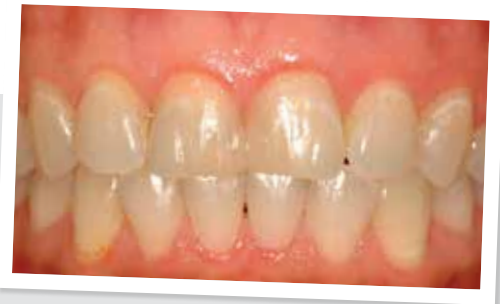Poticny also serves as a consultant and advisor to various dental manufacturers and serves as an editorial board member for multiple dental journals. He is a member of the International Association for Dental Research, the Academy of Computerized Dentistry and the American Dental Association and its component societies.

Whenever a patient needs anterior restorations, it is safe to assume that the aesthetic demand will be quite high. The objective of any clinician working on anterior teeth is to make the treatment look as innocuous as possible—as though we were never there.

Consideration of material for anterior crown applications involves aesthetics, the condition and amount of supporting tooth structure, the need to conceal dark cores or non-matching stump shades, and the presence of parafunctional habits. Full ceramics are considered the gold standard for these applications, but ceramics cover a lot of territory because many factors contribute to the selection of one ceramic over another.

Veneered ceramics that are pressed or layered over high-strength zirconia cores are an option when metal substructures are undesirable. Technically, these are better described as porcelains (silica glass) fused to polycrystalline ceramic (no glass content) cores that can be used to mask underlying conditions. This solution is similar to how metal was used, but eliminates the gray lines in gingival areas and improves the dead look caused by metal's opacity and opaquers used to mask yellow or gray metal.

While zirconia is a definite improvement compared to the optical properties of metals in terms of opacity, it too leaves something to be desired in terms of tooth-like light transmission, fluorescence and



**Fig. 1.** A 42-year-old female patient with existing endodontics and restorative material on teeth 8 and 9.

accurate shading. Most zirconia cores are inherently white and must be shaded with the use of dopants (coloring agents) to reduce the stark white effect. In most cases, pressed or milled ceramics would yield better aesthetic results with the proper application.

Although layered-over-core materials have held their own for decades, the veneered porcelain can chip because of patient habits, accidental trauma and incorrect laboratory fabrication. As a result, monolithic zirconia is also widely used for posterior applications and more recently for crowns in the smile zone.

Being machined from a solid ingot, block or puck with the promise of high strength due to construction simplicity, the one-piece construction principle should render chipping as a virtual non-issue. Monolithic zirconia also allows for minimally invasive preparations for upper incisors requiring thin lingual with very low abrasivity, much like metal was previously used in areas with minimal clearance and high stress.

The following case details a new-generation zirconia that offers strength and monolithic construction with aesthetic versatility for the demanding requirements of restorations in the smile zone. Light transmission closely mimics enamel through the combination of posterior zirconia (tetragonal form) with the cubic form, which provides exceptional strength ( $\geq 800$  MPa) and a vital, life-like appearance. Lastly, a streamlined protocol for adhesive placement will be demonstrated to showcase the results.

### The case

A 42-year-old female patient came in with endodontics that had already been performed on tooth #8. She also had a substantial amount of restorative material on teeth #8 and #9. Her chief complaint was that she did not like the appearance of her front teeth. There was significant wear on the incisal edges and rotations that she wanted corrected. She simply wanted a better-looking shape and appearance for her teeth (Fig. 1).

The preop image demonstrates the original, triangular shape of the teeth that the patient wanted altered. In discussing treatment planning, the patient gave much consideration to three facts:

1. Endodontics had already rendered the teeth non-vital (reducing the importance of being minimally invasive).

2. The teeth were significantly composed of restorative material from prior dental procedures.

3. Modern restorative materials have gotten better at mimicking natural tooth structure in the smile zone and her fear of fake-tooth appearance could be avoided.

These factors made it easy for the patient to accept a treatment plan for crowns.

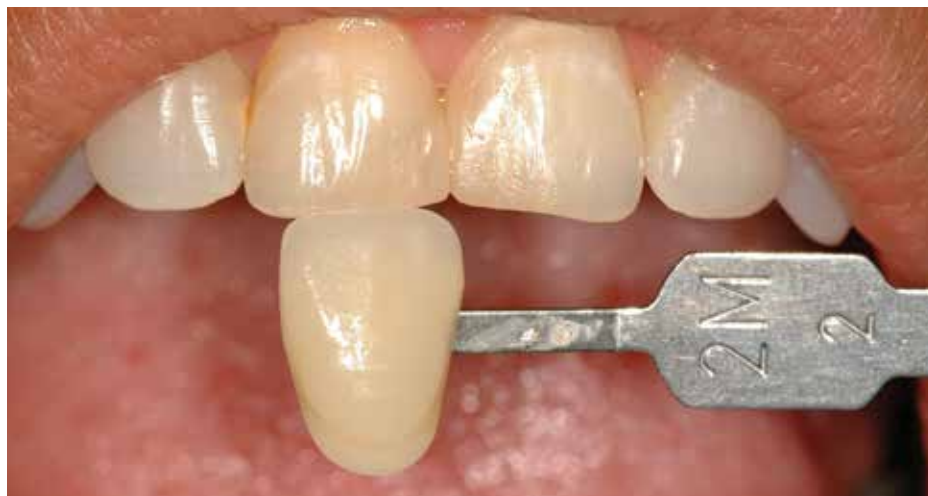

Fig. 2. Determining shade match

### Finding the balance

One of the most challenging things for dentists has been to balance aesthetics with strength in restorations. We know that restorative materials with high levels of glass typically produce the best aesthetic effect, because the glass allows the material to mimic enamel. However, higher glass content leads to a lower accompanying strength. There are times when strength takes precedence, but finding balance with simple solutions should be the stated goal. Current zirconia in its tetragonal form is highly popular for posterior applications due to chip and fracture resistance, full-contour simplicity and ability to be cemented conventionally or adhesively bonded.

Once sintered, zirconia converts to a tetragonal form that is highly resistant to fracture. If a crack develops, the crystalline nature of the tetragonal material transforms to a monoclinic structure and exerts pressure on the crack to stop it from progressing. This property gives it a high flexural strength and better fracture toughness compared to other dental ceramics. However, this strength comes with compromises because the tetragonal form scatters

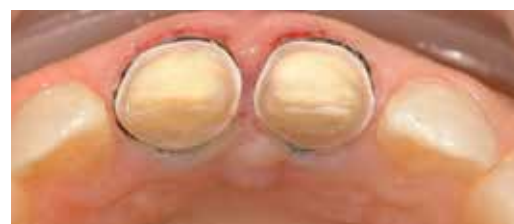

Fig. 3. Minimal preparations were required for using 3M Lava Esthetic

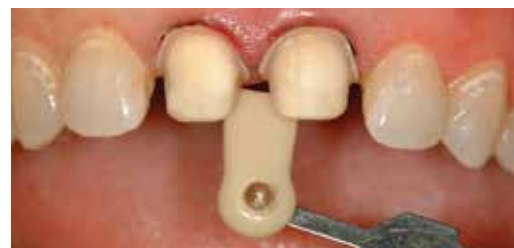

Fig. 4. Minimal preparations were required for using 3M Lava Esthetic

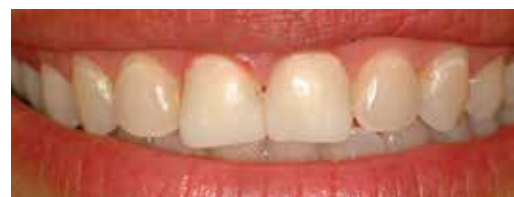

Fig. 5. Temporary material reshaped the geometries of the patient's anterior teeth

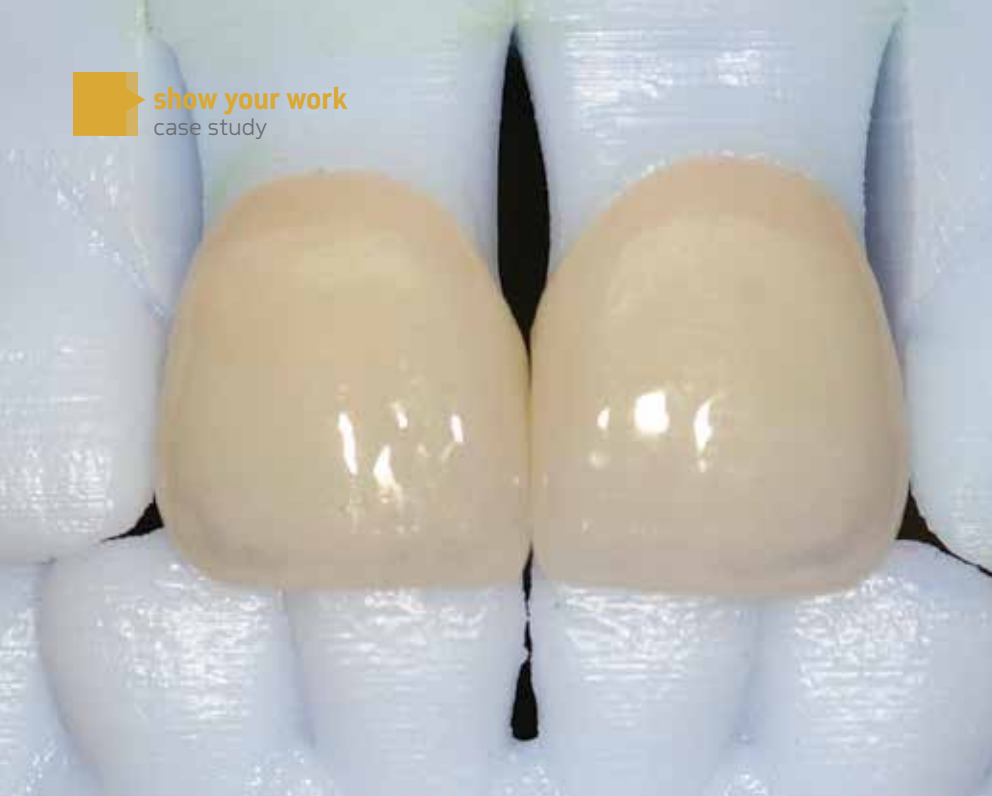

Fig. 6. Lab restorations on SLA model

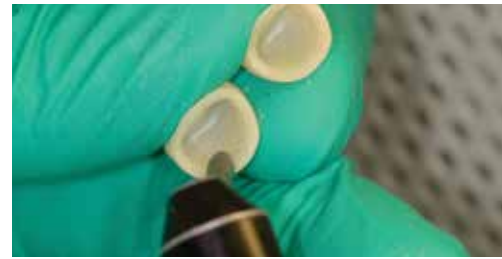


Fig. 7. Sandblasting restorations at one- or two-bar pressure

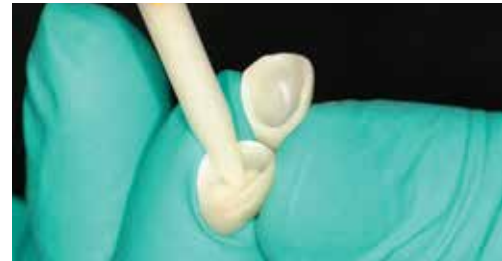

Fig. 8. Dispensing 3M RelyX Unicem 2 Self-Adhesive Resin Cement into 3M Lava Esthetic zirconia restorations

more light than natural teeth, preventing it from mimicking natural dentition.

For this particular case, I used a new full-contour zirconia (Lava Esthetic Zirconia, 3M). The zirconia is modified to incorporate both the tetragonal and cubic phases. This combination boosts light transmission, which improves the appearance and vitality of the material.

Additionally, the product's built-in fluorescence reacts to light like natural teeth without needing additional stains and glazes that are often lost through wear. The zirconia's shading is built in rather than painted on or infused via shading liquids. With this approach, a crown can be positioned with the gradients available in the puck or block and milled to form for true polychromatics that will last the lifetime of the restoration (Fig. 2, p. 33).

Since we were dealing with the anterior teeth, the patient obviously wanted superb aesthetics. The laterals had a bit of a halo effect around the incisal edges and we wanted to achieve that same effect with the restorations.

We started by preparing the teeth and adding composite materials to modestly correct the geometries to allow for optimal milling and fitment. I packed retraction

Current zirconia in its tetragonal form is highly popular for posterior applications due to chip and fracture resistance, full-contour simplicity and ability to be cemented conventionally or adhesively bonded.

cord around each tooth, and then used retraction paste (3M Retraction Capsule) to reduce the potential for bleeding, open the sulcus and reduce crevicular weeping along with the cord. It can be used alone or with cord, I prefer both for optimal results (Figs. 3 and 4, p. 33).

We digitally scanned the impressions and made temporaries. We sent our laboratory a prescan in addition to the desired restoration position so they could overlay the patient's precondition with the final position. This allowed us to achieve proper alignment for the midline and desired incisal correction for 8 and 9 (Fig. 5, p. 33).



### Show your work in Dentaltown!

If you've got a case you think might be a great study for Show Your Work, email editor Sam Mittelsteadt:

**sam@dentaltown.com.**

Be sure to include a sentence that sums up why the case is so special to you, to help us review and select the best contenders for publication.

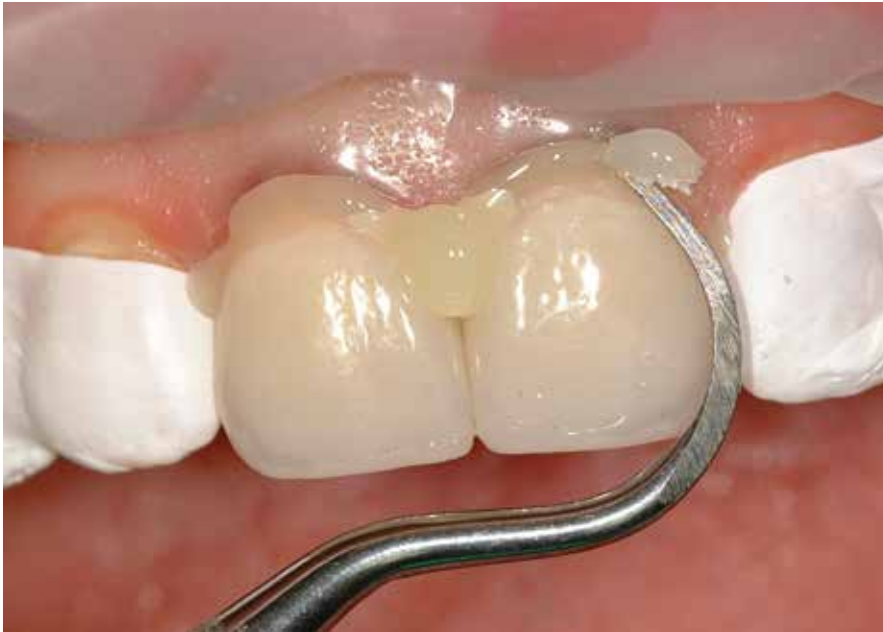

Fig. 9. Crowns seated post-one-second light cure, easy cement removal

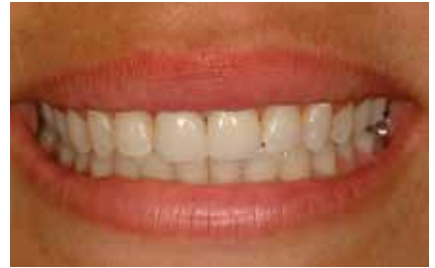

Fig. 10. Restorations immediately post-cement cleanup

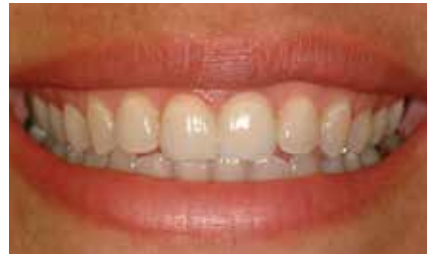

Fig. 11. Restorations one week postoperatively

## Products used

- 3M Lava Esthetic Fluorescent Full-Contour Zirconia Disc
- 3M Retraction Capsule
- True Definition Scanner, 3M
- RelyX Unicem 2 Self-Adhesive Resin Cement, 3M

Once we received the restorations from the lab, we removed the temporaries, cleaned up the residual cement, created a proper field for placement, and packed a little cord around the teeth to prevent any fluid contamination to the adhesive interface at the margins of the crown (Fig. 6, p. 34).

We cleaned the teeth, verified the restoration fit, and abraded the restorations with aluminum oxide at two-bar pressure to remove contaminants like phosphates present in saliva, which interfere with the self-adhesive cement, and to energize the zirconia surface to optimize adhesion with our resin-based, self-adhesive cement.

If the lab has presandblasted, try-in your restorations, and clean with a sodium hypochlorite rinse followed by a water rinse prior to final placement (Fig. 7, p. 34).

## Simple cementation

Lava Esthetic zirconia requires a resin cement for aesthetic purposes because of its inherent translucence. Self-adhesive resin cements are ideal due to aesthetic potential and simplicity of application.

3M's RelyX Unicem 2 is a self-etching adhesive resin cement that requires no other formulations or chemical applications to the teeth, including etchants, disinfectants or desensitizers. For cement usage, the teeth can be cleansed with flour of pumice, dried and left in a moist condition. This will provide the optimal conditions for maximum adhesion with excellent margin sealing (Fig. 8, p. 34). It is not necessary to use a primer (MDP) when using Unicem 2 with zirconia as its proprietary chemistry yields sufficient bond strengths to zirconia in most cases.

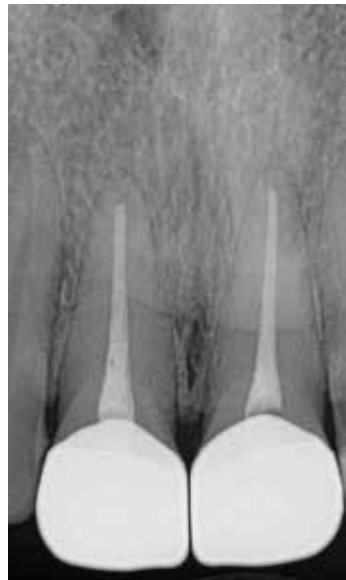
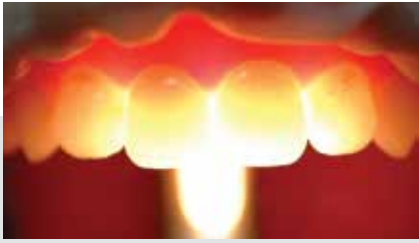
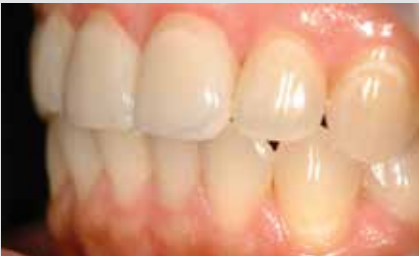Fig. 12. Radiograph one-week postop



**Fig. 13.** Lava Esthetic zirconia allows restorations to fluoresce and look alive in UV light



**Fig. 14.** Close-up left lateral view one week postoperatively

The cement can be dispensed through the syringe, placed into the crown and seated after you've cleansed the restoration and the tooth. At that point, you can cure for a one-second interval on the buccal and lingual surface (consider a light with a timer) and peel the cement away cleanly with a scaler, floss through the contacts, light-cure again for 20 seconds per surface or have the patient close for five minutes, clean up and you're done (Fig. 9). The whole process of cementing the restorations took about 30 minutes (Fig. 10).

### **Postoperative recap**

I had the patient come back one week following her crown treatment to check on the restorations (Figs. 11–14). She was ecstatic and commented how many of her friends had crowns placed over their front teeth with less-than-desired results. She also liked how she had more latitude when eating because of low likelihood for chipping. Unbelievably, she brought me gifts, including a home-baked cake for the office and a dress shirt for me—and no, I did not make this up! ■